

Central Vein Stenosis and Central Lines in CKD Patients Referred for Venograms

A. Dhillon¹, L. Salfity¹, P. Abraham¹, R. Morgan², A. Wadoodi¹

¹Renal Transplant Surgery, St George's Hospital NHS Foundation Trust, London, UK

²Interventional Radiology, St George's Hospital NHS Foundation Trust, London, UK

AIMS

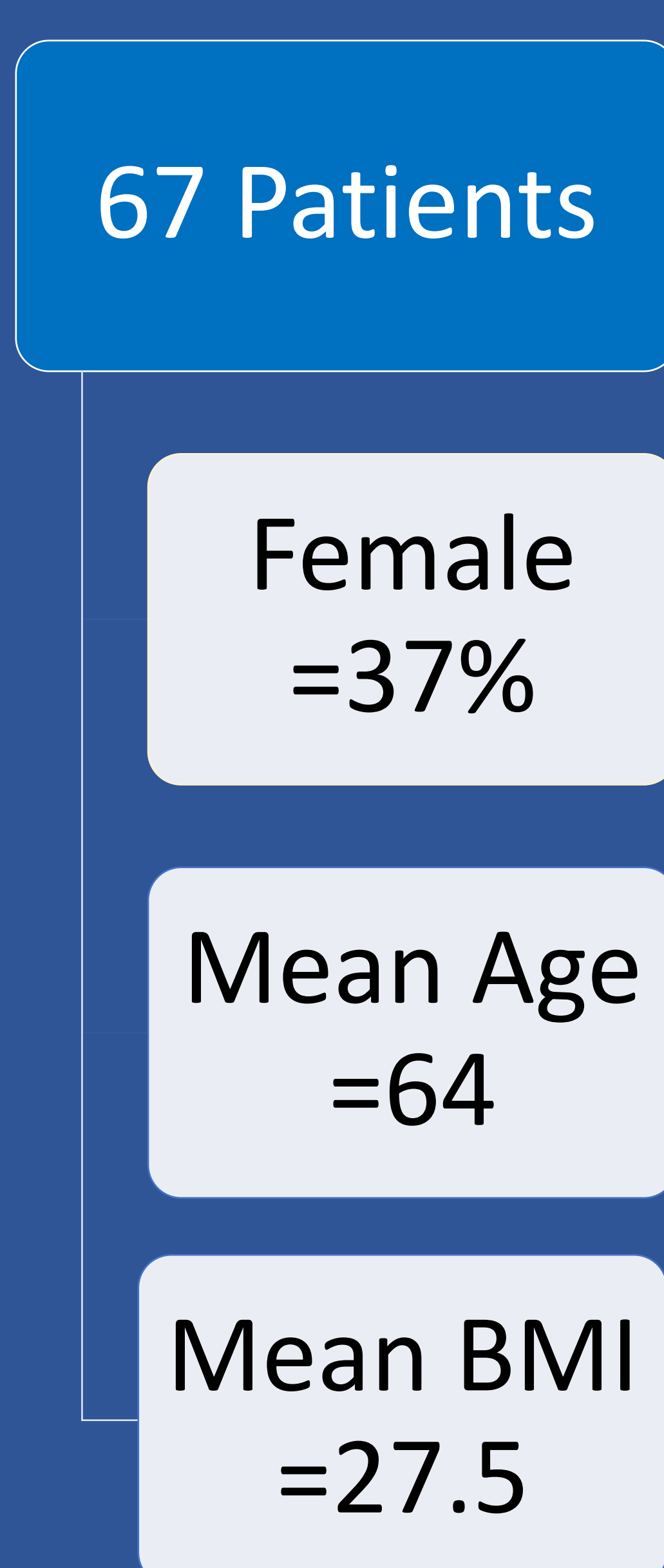
Central Vein Stenosis (CVS) can occur following insertion of central lines; however whether catheter site increases risk for CVS is unclear. This study aims to determine whether having a left versus right-sided catheter is associated with increased incidence of CVS.

METHODS

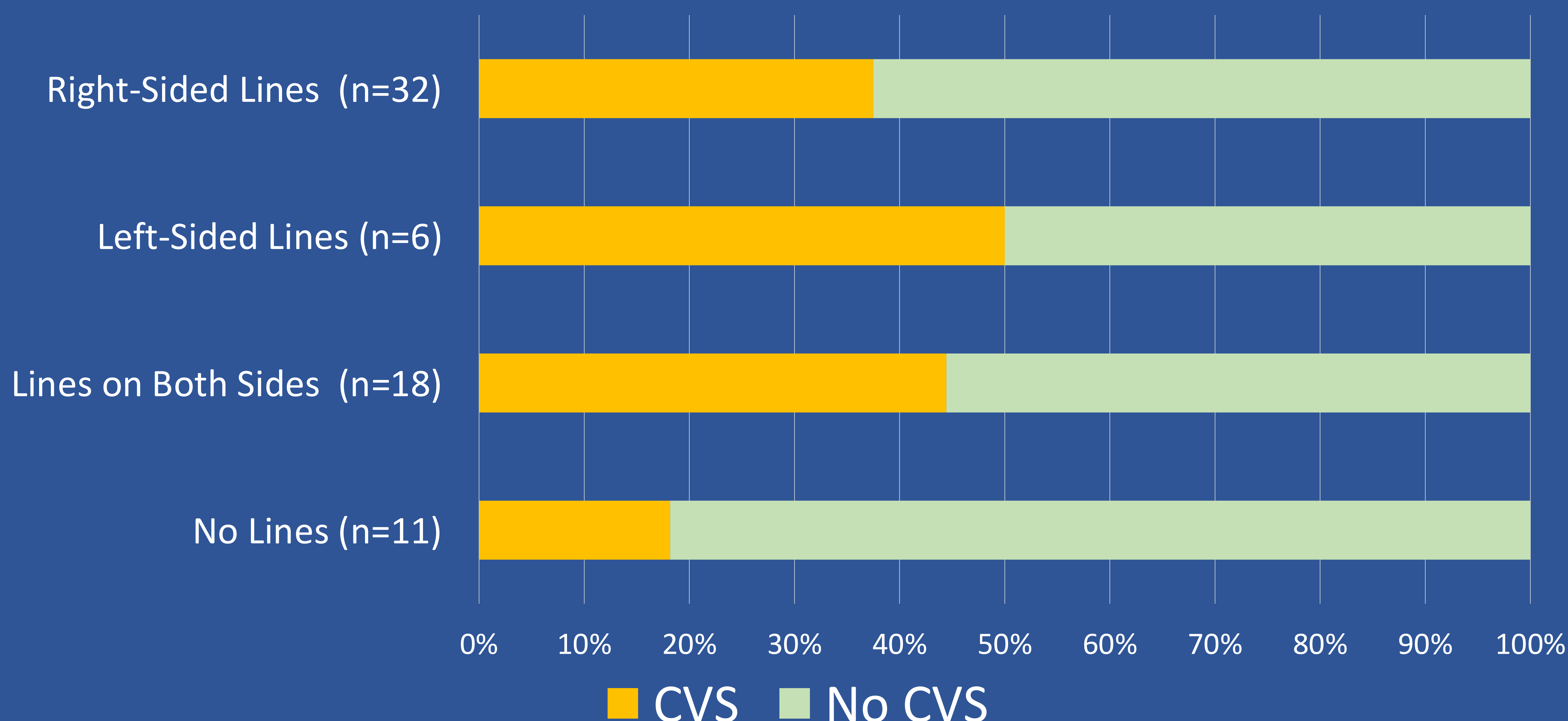
We conducted a retrospective analysis of haemodialysis patients referred for venograms from 2017 to 2020. Patients were compared for demographics. Statistical analysis was used to establish the relationship between CVS and catheter side.

RESULTS

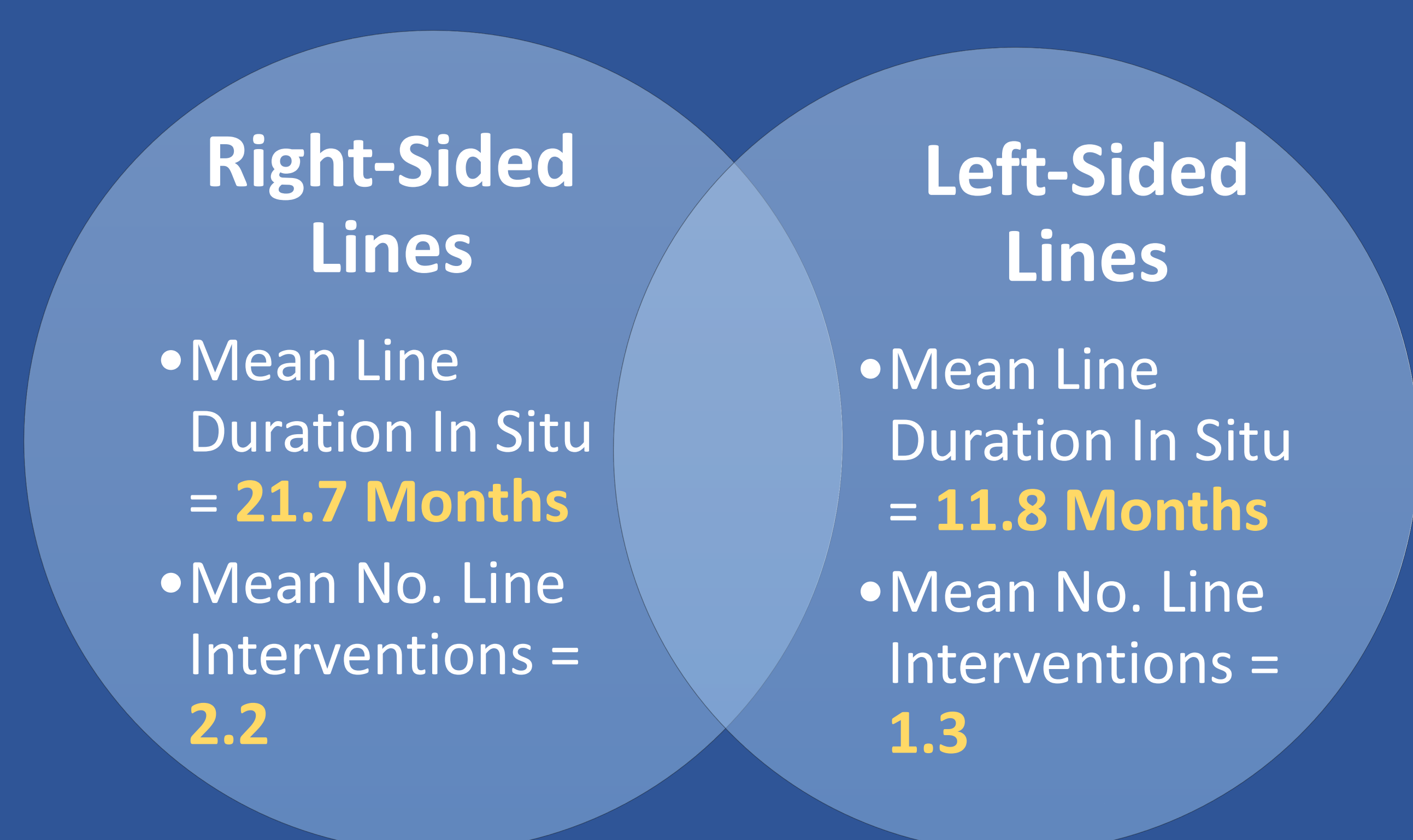
a) Demographics



b) Line History and Proportion of Patients with CVS



c) Right-side Vs Left-side Lines Duration In Situ and Interventions



a) In total, 67 patients who underwent mapping venograms prior to fistula surgery. The mean age was 65 (± 11.4), average BMI was 27.5 (± 7.0) and women accounted for 37%.

b) 32 patients had a history of exclusively right-sided lines, and 12 (37.5%) of these had CVS. 6 patients had only left-sided lines, and 3 (50%) had CVS. 18 patients had lines on both sides, and 8 (44.4%) had CVS. 11 patients had no prior line history, and only 2 (18%) had CVS.

c) For right-sided lines, mean line duration was 21.7 months (maximum 132, minimum 1), and for left-sided lines, this was 11.8 months (maximum 36, minimum 2). The average number of previous line interventions was 2.2 for right-sided catheters and 1.3 for left-sided catheters.

CONCLUSION

The cohort of only left-sided lines had an increased prevalence of CVS, despite left lines having a shorter mean duration in situ and less previous interventions. However, it is acknowledged that the total number of exclusively left-sided lines was considerably less and more data needs to be collected to explore this relationship.

References

Fourastie, V., Godeau, B., Lejonec, J. and Schaeffer, A., 1985. Left Innominate Vein Stenosis as a Late Complication of Central Vein Catheterization. *Chest*, [online] 88(4), pp.636-638. Available at: <https://www.sciencedirect.com/science/article/pii/S0012369215342586?casa_token=FzrF3yGoCnMAAAAA:V6BKsWNUFwtHaM6P0uP9joRhJ9g_AYt-uWQET-s9Ty21XPmSfo3iV0pW4zQgI4fSYsYITP9LEp> [Accessed 13 September 2020].
MacRae, J., Ahmed, A., Johnson, N., Levin, A. and Kiaii, M., 2005. Central Vein Stenosis: A Common Problem in Patients on Hemodialysis. *ASAIO Journal*, [online] 51(1), pp.77-81. Available at: <https://journals.lww.com/asaiojournal/Fulltext/2005/01000/Central_Vein_Stenosis_A_Common_Problem_in_15.aspx?casa_token=I8VQ40Rz0QAAAAA:qkn6hETHyCVchRwkJ596in8ekXx8rncOrTscdKJ6KRny5m-xMK7U1kQ8w1Iitm_YyAbpet2LXcmQroYCeZDq19vhQ> [Accessed 13 September 2020].
Zulkarnain, A., Kardanakhishvili, Z. and Baykov, B., 2020. P1319AMBIGUOUS RESULTS OF CENTRAL VEIN STENOSIS ENDOVASCULAR TREATMENT IN HEMODIALYSIS PATIENTS. *Nephrology Dialysis Transplantation*, [online] 35(Supplement_3). Available at: <https://academic.oup.com/ndt/article-abstract/35/Supplement_3/gfaa142.P1319/5852045?redirectedFrom=fulltext> [Accessed 13 September 2020].